

13.4 Liposuction

W. Schmeller

In recent years, liposuction has become increasingly popular and is currently applied with a great deal of success in lymphology (lipedema and lymphedema management). It was first used by Georgio and Arpad Fischer in Rome in the mid-1970s and refined by Yves-Gerard Illouz in Paris in the early 1980s. By the early 21st century, liposuction had become the most frequently performed cosmetic operation in the world. An estimated 500,000 liposuctions are performed in the United States each year, and more than 150,000 in Germany. Medical indications are playing an increasing role in the performance of liposuction.

13.4.1 Indications

The goal of liposuction is the reduction of localized fatty tissue to produce well-proportioned body contours.

While dieting results in the number of adipocytes remaining the same, with only the individual cell content reduced, liposuction leads to permanent removal of localized concentrations of adipocytes. Interestingly, although the fat volume is reduced with liposuction, the method does not result in weight loss. Thus it is not suitable for treating overweight or generalized obesity. In these cases, however, by improving the patients' body contours, their motivation to modify their eating and leisure habits may be considerably increased.

In the last 10 years, liposuction has been used more and more frequently in cases of disease, including giant lipoma, symmetrical lipomatosis (Launois-Bensaude syndrome), so-called "buffalo neck" in Cushing's syndrome, lipomatosis dolorosa (Dercum's disease) and gynecomastia or lipomastosis. The procedure is now also used for certain forms of lymphedema.

Treating lipedema has great practical relevance. Liposuction, in combination with traditional conservative therapeutic measures, has contributed to huge advances in the treatment of lipedema (1, 2). In 2004, liposuction was added to the guidelines for lipedema management of the lower extremities (3). Fat deposits can also be removed from the upper and lower arms, hips, buttocks and stomach.

The best results can be achieved in stage I and II. In severe cases, i.e. stage III, the condition can also be improved, however, the total volume

to be removed is much larger, and the retraction of the surrounding skin layer is often poorer. In addition, due to the usually older age and, frequently, obesity of the patients, secondary disorders such as hypertension, diabetes mellitus and heart failure are often present that make surgery more difficult. The earlier the treatment, the better.

13.4.2 Surgical Aspects

Liposuction's meteoric rise in popularity can largely be attributed to three developments: tumescent local anesthesia (TLA), the introduction of blunt-tip microcannulas and the use of vibrating suction cannulas (power-assisted liposuction). This has considerably reduced the risk of the procedure for patients, is much easier on the tissue and has made results much more predictable for the physician.

13.4.2.1 Tumescent Local Anesthesia

Tumescent local anesthesia is a regional anesthesia in which the subcutis is infiltrated with a large volume of a diluted anesthetic, causing the tissue to swell (Latin: tumescere). The procedure was first described in 1987 by American dermatologist and pharmacologist Jeffrey Klein and later varied and refined, primarily by surgical dermatologists (4, 5). The mixture, which was developed in California, originally consisted of physiological saline solution and the local anesthetic lidocaine. In Germany, the anesthetic of choice was prilocaine, which had a lower cardiotoxicity. Recently a combination of lidocaine and prilocaine has proven to be effective (6). The original concentration of 0.1% has been reduced to 0.037% (Table 13.4-1). Tumescent local anesthesia also contains adrenaline (reduces blood flow and systemic reabsorption of the local anesthetic, reduces hematoma), sodium bicarbonate (buffers the H⁺ ions, prevents "burning" during infiltration and accelerates the onset of activity of the anesthetic) and triamcinolone (anti-inflammatory, stimulates circulation, induces mild euphoria).

The areas to be suctioned are marked with a waterproof felt-tip pen prior to surgery with the patient in a standing position (Figure 13. 4-1). The solution mixture is then infiltrated into the subcutaneous tissue with an infusion pump, for example, an infusion distribution system (Figure 13.4-2a) until the tissue is full and taut ("superwet technique"). Depending on the size, elasticity of the tissue and number of body areas, generally between two and eight liters are required. The fact that some residual fluid remains in the tissue guarantees that the patient will remain pain-free for 18 hours, which makes the postoperative period relatively

Prilocaine 2%	10.0 mL
Lidocaine 2%	10.0 mL
Adrenaline 1 : 10,000	0.66 mL
Sodium bicarbonate 8.4%	6.0 mL
Triamcinolon 40 mg	0.33 mL
Saline (NaCl 0.9%)	1000.0 mL
	1026.99 mL

Table 13.4-1)

Composition of 0.037% solution for tumescent local anesthesia

comfortable. After this period, patients frequently report symptoms resembling sore muscles that, however, generally do not require pain relief treatment.

In addition to the probably direct anti-thrombotic impact of tumescent local anesthesia, mobilizing the patient both during (changing position on the operating table to achieve optimal suction position) and after (standing up to check the results, postoperative ambulation) the procedure considerably reduces the risk of thrombosis.

In general, tumescent local anesthesia has made liposuction easier, safer and less expensive. General anesthesia and sedation are not required, blood loss is minor and the patient is mobile immediately after the procedure, meaning that liposuction can be performed as an office procedure. However, TLA requires experience. At the end of infiltration, the large amounts of fluid make the tissue taut and elastic, eliminating the contours. The surgeon must follow the markings exactly. The remaining fluid also makes assessing the results difficult. However, if the operator has sufficient experience, the advantages of this procedure far outweigh the disadvantages (Table 13.4-2 and Table 13.4-3).

13.4.2.2 Microcannulas

The dilution and softening effect of the tumescent local anesthesia solution permit the use of very thin, blunt-tipped cannulas with openings on the side. Currently most suction cannulas used are 3 to 4 mm in diameter (Figure 13.4-2b), allowing a largely atraumatic procedure that

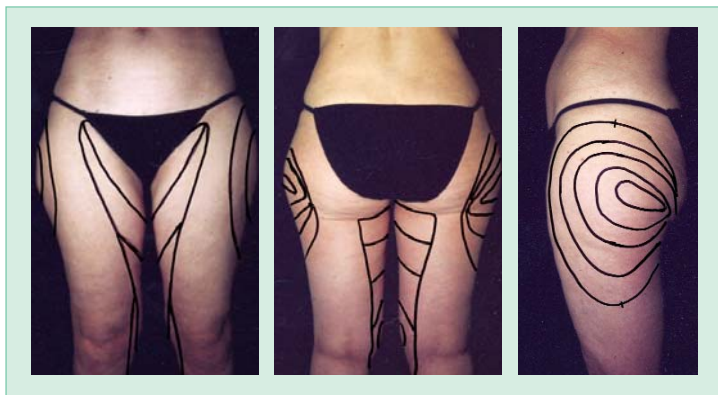


Figure 13.4-1)
Marked body parts prior to liposuction

conserves the subcutaneous structure of the connective tissue. This permits regular fat aspiration with cosmetically positive results without skin retraction or dimpling.

13.4.2.3 Power-assisted Liposuction

In recent years, suction cannulas have been developed that are set in vibration with a motorized grip (Figure 13.4-3). With power-assisted liposuction (PAL), the oscillations (4,000/min) that differ from the more sluggish vibrations of the adipose tissue allow the vibrating suction cannula to pass through the connective tissue structures without them being aspirated into the cannula. This considerably reduces the shear forces, and the fat homogenized by the tumescent local anesthesia solution can enter the cannula more easily (7). The high amounts extracted per time unit shorten the length of surgical procedures and reduce intra and post-surgical pain. In addition, recovery rates are shorter. Strain on the operator's arm is reduced (8), especially in the case of subcutaneous fibrosis and problem areas such as body areas with large amounts of fibrous tissue in athletic patients. This is significant, considering that for extensive lipedema often one to two hours of suctioning are required (9).

13.4.2.4 Other Developments

After the expectations of ultrasonic liposuction first described by Scuderi in 1987 failed to materialize and the procedure resulted in serious complications such as skin necrosis and nerve pain (10); in Germany this

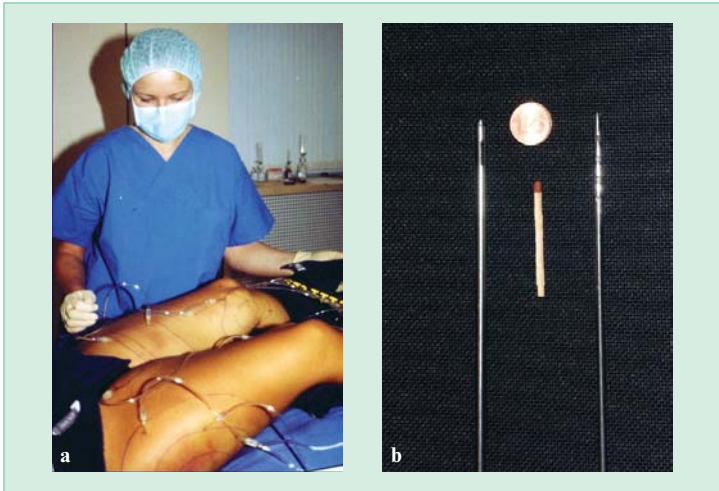


Figure 13.4-2)

a) Infiltration of tumescent solution of exterior and interior thighs

b) Blunt microcannulas; size comparison

method has largely been abandoned. So-called lipo-pulsing (destroying the adipocytes using high-frequency electromagnetic waves prior to liposuction) and water-assisted liposuction (variation of the tumescent technique with lower amounts of fluid but greater trauma) have not become established.

13.4.3 Practical Aspects

Prior to performing liposuction, the patient undergoes a thorough clinical examination and extensive consultation. Examinations using diagnostic instrumentation such as ultrasound or lymphoscintigraphy are rarely necessary.

13.4.3.1 Preoperative Procedures

After photographing and marking the area to be aspirated with a waterproof felt-tip pen and preanesthetizing the incision sites, infiltration of the tumescent local anesthesia solution is carried out preoperatively, involving different stages of tumescence.

Advantages

- Complete analgesia of larger parts of the body
- Simple handling
- Little bleeding during surgery, minor hematomas following surgery
- Improved resorption of hematomas due to diluting effect of TLA solution
- Minor pain postoperatively
- Safe in comparison to other forms of local and general anesthesia
- Antibacterial effect of TLA solution
- Reduction of number of bacteria/germs due to draining (“washing” effect) of solution within the first days after surgery
- Antithrombotic effect of TLA solution
- No loss of fluid during surgery, no need for infusions
- Dilution of fat, therefore suction with microcannulas possible
- Patient is able to bring himself/herself to an optimal position for suction
- Direct evaluation of result in standing position after surgery allowing final corrections
- Low rate of complications

Table 13.4-2)

Advantages of tumescent local anesthesia (TLA)

First, suprafascial hydrodissection takes place along the septae of the fibrous tissue dividing the adipose tissue. Increasing volume and rising pressure in the tissue force the fluid to surround the individual fat lobes (perilobular infiltration). After approximately 30 to 60 minutes of infiltration, the solution penetrates the fat lobes (intralobular infiltration),

Disadvantages

- Long time needed for complete analgesia
- “Wet” surgery
- Evaluation of body contour difficult due to high fluid content in subcutaneous fatty tissue layer
- Not suitable for patients who do not want to “see and hear”
- Patient awake and conscious during procedure, possibly requiring verbal reassurance, relaxation techniques, etc.
- Minor risk of inadvertent intravenous TLA injection

Table 13.4-3

Disadvantages of tumescent local anesthesia (TLA)

leading to a general homogenization of the fatty tissue area. After a resting interval of approximately 30 minutes and a short re-infiltration phase (approximately 15 minutes), aspiration is carried out at high turgor of the subcutaneous tissue and pale skin (due to vascular constriction secondary to adrenaline, and to vascular compression secondary to increased tissue pressure).

13.4.3.2 Intraoperative Procedures

Liposuction is carried out via several approximately 4-mm incisions at inconspicuous skin sites with negative pressure of approximately 0.8 atmospheres. The cannula is then used to aspirate the fat in a fan-like manner with the so-called criss-cross technique described by Fournier. Each area is aspirated overlapping from different angles; however, on the legs and arms the main direction of aspiration is the lengthwise axis of the extremities. Generally, the right hand guides the cannula back and forth, while the left hand checks the position of the tip of the cannula in the subcutaneous region by palpating the skin surface. Aspiration is primarily carried out in the lower and mid-subcutaneous tissue. The upper subcutaneous tissue should be reduced as little as possible in order for the

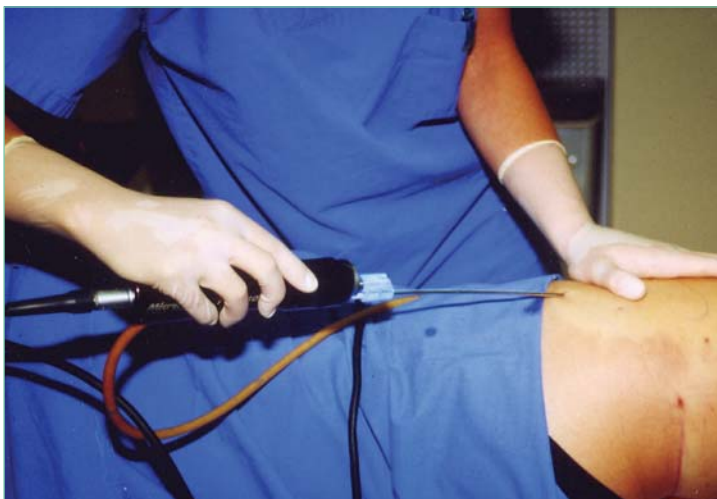

Figure 13.4-3)

Power-assisted liposuction. The motor in the grip causes the cannula to vibrate. The aspirated fat in the tube is visible

soft tissue layer to remain smooth without dimpling and retraction. Duration of aspiration is between 30 and 120 minutes, depending on the size and number of body areas.

Although the contours of the affected area are eliminated by the remaining concentration of liquid at the end of the procedure, the aspiration is likely to be successful if carried out by an experienced operator. The aspirated fat is collected in a plastic container and floats on the aspirated tumescent local anesthesia solution; the red color in the photograph is due to several drops of blood (Figure 13.4-4a). According to international standards, a maximum of four liters of fat should be aspirated. Depending on the size and number of body parts, generally between one and three liters are aspirated during a procedure for lipedema. Megaliposuction carried out in the past involving the aspiration of ten or more liters of fat are considered obsolete by today's standards.

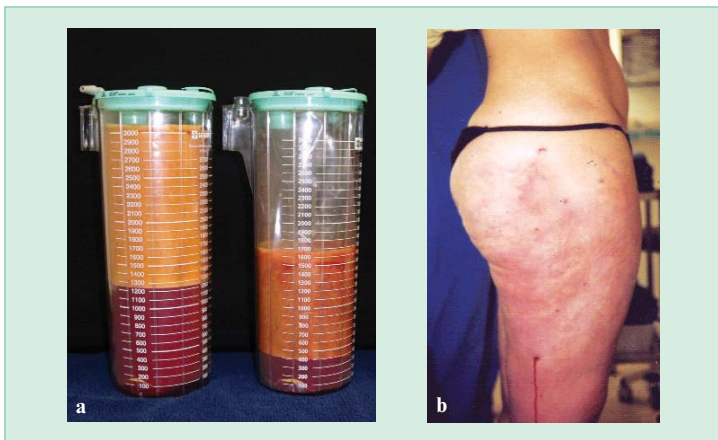


Figure 13.4-4)

a) Aspiration container with pure fat at the top and reddish tumescent solution (drops of blood) below

b) Immediately after liposuction, patient is checked in a standing position. Tumescent solution drains from lower incision site

13.4.3.3 Postoperative Procedures

Directly after the procedure, the patient stands up, so the results can be assessed in a standing position. This will cause some of the remaining tumescent anesthesia solution to escape from the lowermost incisions (Figure 13.4-4b). They are not closed with sutures but are taped with a fluid-permeable adhesive bandage. Leakage of the solution is heaviest within the first several hours following the operation. Compresses placed under a compression girdle absorb this flow. Drainage continues for another one to three days.

After swelling has reduced the next morning, the difference from the original condition is striking (Figure 13.4-5). The patient may now shower and may “go about business as usual.” General activity is not restricted. Many operators recommend taking antibiotics for three to five days to prevent infection. Sports activities may be resumed after one or two days. Patients are advised to avoid using a sauna (to prevent swelling) and to avoid exposure to direct ultraviolet radiation (to prevent postsurgical hyperpigmentation) for approximately four weeks. The first outpatient follow-up should generally take place after two to four weeks.

Temporary wound edema frequently occurs in the following days. This can be reduced or even prevented by resuming manual lymph drainage as early as the next day or especially by wearing a snugly fitting compression girdle. The patient should wear the girdle for a total of one month, day and night for the first week, and during the day for the remaining three weeks. If the patient wore compression sleeves or stockings before the operation, this may be resumed. However, often new, more snugly fitting, sleeves or stockings are required. Since the lipedema-specific swelling is generally reduced after the operation, the patient may be able to be fitted with garment with a lower compression grade.

Postsurgical subcutaneous scarring makes the skin tauter. The three-dimensional shrinking process that takes place over a period of several weeks prevents the skin from drooping and is responsible for the good results, even with large volume reduction. While patients are often afraid that excess skin must be removed after liposuction, this is required only in exceptional cases, for example, in the upper arm in older women. Since the tightening process varies from individual to individual and takes several months, results should not be considered to be final until at least 6 months after liposuction.

The postoperative induration of the subcutaneous tissue caused by scarring often involves dysesthesia, with patients reporting numbness, tingling or similar unpleasant sensations. All these symptoms disappear on their own within several weeks.

13.4.4 Results

Overall liposuction results for lipedema are good. This applies to both objective changes in body contours as well as the reduction of symptoms as reported by patients using self-assessment scales presented in Figure 13.4-6 to Figure 13.4-8 (2). The marked improvement in quality of life across the board is remarkable.

If several body areas are affected, requiring more than one session, the procedures should be scheduled at least 4 weeks apart. In severe cases in which a high volume of fat remains after the procedure, the same area may be reaspirated after six to twelve months, which leads to a more satisfactory outcome.

With the use of the new methods, lymph vessel damage resulting in secondary lymphedema seen earlier has no longer been described, in either clinical or experimental settings. Anatomical investigations after liposuction also did not reveal damage to epifascial lymph collectors (11).

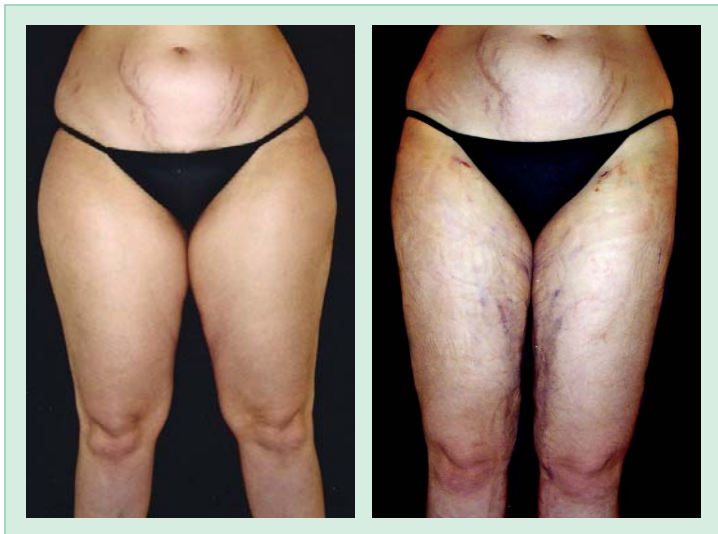

Figure 13.4-5)

Before liposuction and morning after liposuction after removing 4,000 mL fat from the exterior and interior thighs and interior knees. Painless hematomas on the inner thighs and knees

When liposuction is performed by physicians with inadequate training (“weekend courses”), cosmetically unsatisfactory results and complications may be seen. In assessing these results, the particular method (large sharp cannulas or blunt microcannulas) and anesthesia (“wet” or “dry” technique) must be discerned. In addition, the results of liposuction performed in the 1980s may not be compared to those from the 21st century.

13.4.5 Side Effects and Complications

Complications during and after liposuction with tumescent local anesthesia are listed in Table 13.4-4. Investigations carried out in large patient groups (over 15,000 patients) showed that complications are generally minor and rare (12).

Normal, temporary side effects include the previously mentioned muscle-ache-like symptoms lasting several days, minimal ecchymoses, temporary edema and temporary dysesthesia and tissue induration in the first

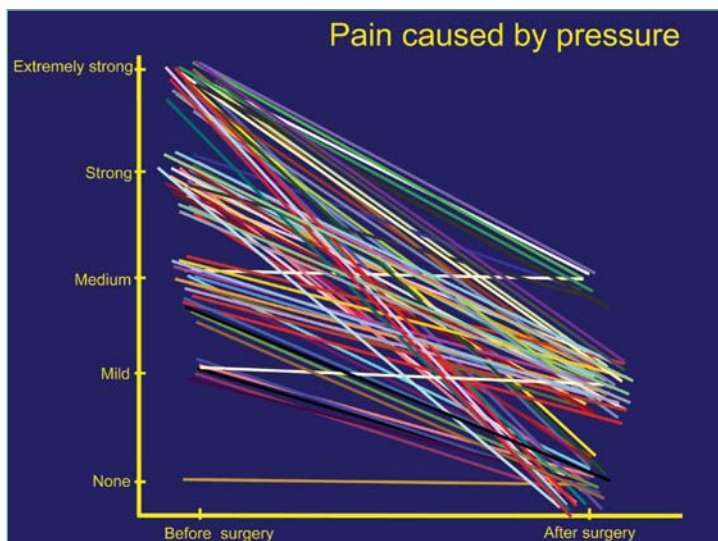


Figure 13.4-6) Improvement in tenderness following liposuction. Self-assessment by 71 patients

weeks. Large hematomas, seromas and wound infections are rare. Longer term edema (persisting for a period of many weeks), observed primarily after liposuction of the calf, is rare. Irregularities ranging from “oversuctioning” to bumpy skin and asymmetries result from inadequate experience of the surgeon. In patients with very low blood pressure, a tendency to collapse may exist on the day of surgery and in very rare cases, during the following days as well. Risk of thrombosis is reported to be between 0.05% to 0.1% (6), generally involving patients with risk factors including the combination of overweight, oral contraceptive use and nicotine abuse on the one hand, and those with a family history of clotting disorders such as Factor V Leiden mutation on the other. No cases of pulmonary or fat embolism during correctly performed tumescent local anesthesia have been reported in the international literature (13).

Deaths, however, resulting from liposuction have been reported in the literature, however. For example, in Germany a retrospective analysis on cosmetic liposuction was carried out from 1998 to 2002. The evaluation of 1,150 surveys revealed 70 severe complications, including 19 deaths.

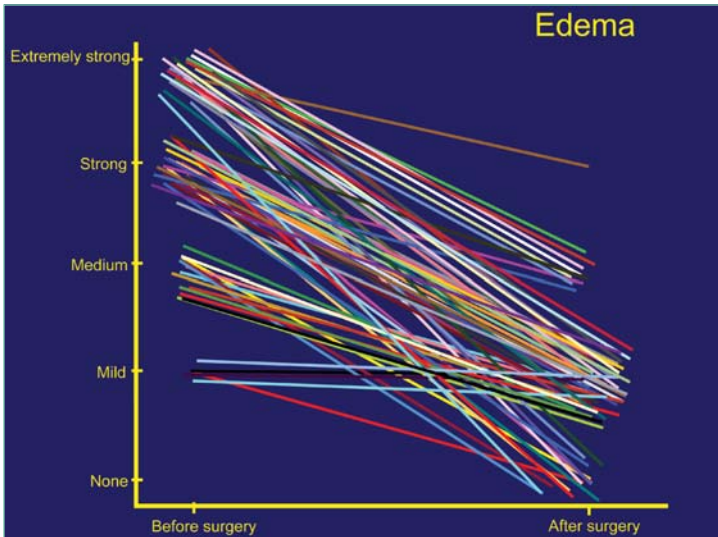


Figure 13.4-7)
Improvement in tendency toward swelling

The complications involved postoperative infections (necrotizing fasciitis, gas gangrene, streptococcal sepsis), organ perforation, secondary hemorrhage, cardiac arrest and hyper and hypohydration (14, 15). Unfortunately, the literature does not report whether or not in these cases liposuction was actually performed in accordance with the nationally and internationally established guidelines; frequently it is not (16, 17). In a number of cases, the patients were obese (BMI > 30); frequently the complications also occurred when tumescent local anesthesia was combined with general anesthesia and when liposuction was combined with other procedures, neither of which corresponds to the recommended procedure.

The textbook on liposuction published in 2003 (18) contains a current overview of the safety and risks associated with tumescent liposuction. In our own experience, the majority of complications occur when guidelines and recommended precautionary measures for performing liposuction are ignored (19). In summary, if performed correctly by experienced surgeons, liposuction is a low-risk procedure with few associated

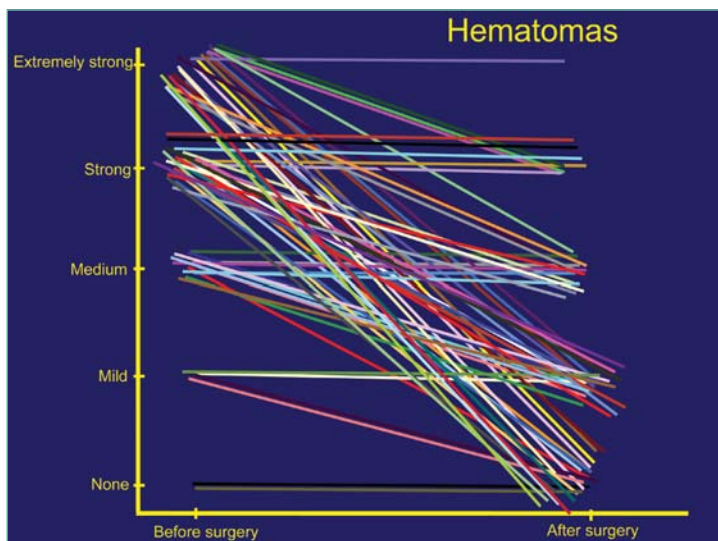


Figure 13.4-8)
Reduction in tendency to develop hematomas

complications. For the patient, choosing an experienced surgeon is crucial (20,21).

13.4.6 Contraindications

Generally, it is not liposuction itself that is contraindicated, but the tumescent local anesthesia due to the side effects of the local anesthesia (22), including rare allergic reactions to amide local anesthesia. If the patient is allergic to parabene, preservative-free 5 mL ampoules may be substituted for the usual 50 mL ampoules.

Since prilocaine and lidocaine have a negative inotropic effect that can negatively impact cardiac conduction, patients with heart failure, bradycardia, AV block and arrhythmia should not be treated. In patients with glucose-6-phosphate dehydrogenase deficiency, methemoglobin formation after administration of prilocaine may occur; hemolytic anemia is not clinically detectable below a dose of 5 g/dL (20%). As a precaution, lidocaine only may be used in these cases.

- Irregularity of body surface, wrinkling, dimpling, asymmetry
- Hematoma
- Seroma
- Wound infection, septicemia, septic shock
- Allergic reaction
- Formation of methemoglobine following infiltration of prilocaine
- Edema for weeks/months, especially after liposuction of lower legs
- Keloid formation
- Hyperpigmentation
- Thrombosis

Table 13.4-4

Reported side effects and complications following liposuction

Old age of the patient is not a contraindication; the patient's biological age is significant. Thus, liposuction is indicated in 70-year old patients in overall good physical condition. Our oldest patient was 77 years old.

Current academic opinion considers lipolymphedema as a contraindication for liposuction. Whether or not this will continue remains to be seen. The fact that liposuction reduces the edema content of the legs suggests that the lymphedema component will be improved as well. Our initial experience with a small group of patients confirms this.

13.4.7 Conclusions

As a result of new developments in local anesthesia and suction cannulas, when performed by experienced surgeons, liposuction is an efficacious procedure with few complications. The localized fat deposits in lipedema can be effectively removed, and a harmonious and aesthetically pleasing physical appearance can be achieved. When guidelines for li-

posuction are complied with, the method has few complications and produces excellent results. The huge enhancement of quality of life is considered by patients to be a revolution in lipedema therapy.

13.4.8 References

1. Meier-Vollrath I, Schneider W, Schmeller W. Lipödem: Verbesserte Lebensqualität durch Therapiekombination. *Dtsch Ärztebl* 2005; 102: A 1061-1067.
2. Schmeller W, Meier-Vollrath I. Lipödem: Ein Update. *LymphForsch* 2005; 9 (1): 10-20.
3. Wienert V, Földi E, Schmeller W, Rabe E. Leitlinie Lipödem der Beine. *Phlebologie* 2005; 34: 42-44.
4. Klein JA. The tumescent technique for liposuction surgery. *Am J Cosm Surg* 1987; 4: 263-267.
5. Klein JA. Tumescent Technique. *Tumescent Anesthesia & Microcannular Liposuction*. St. Louis, Philadelphia, London, Mosby, 2000.
6. Sattler G, Sommer B. Bedeutung und gegenwärtiger Stand der Liposuktion. *MÄC* 2001; 1: 32-40.
7. Coleman WP 3rd. Powered liposuction. *Dermatol Surg* 2000; 26: 315-318.
8. Coleman WP 3rd, Katz B, Bruck M, Narins R, Lawrence N, Flynn TC, Coleman WP, Coleman KM. The efficacy of powered liposuction. *Dermatol Surg* 2001; 27: 735-738.
9. Katz BE, Bruck MC, Coleman WP 3rd. The benefits of powered liposuction versus traditional liposuction: A paired comparison analysis. *Dermatol Surg* 2001; 27: 863-867.
10. Schefflan M, Tazi H. Ultrasonically assisted body contouring. *Aesthetic Surg* 1996; 16:117-122.
11. Hoffmann JN, Fertmann JP, Baumeister RG, Putz R, Frick A. Tumescent and dry liposuction of lower extremities: differences in lymph vessel injury. *Plast Reconstr Surg* 2004; 113: 718-724; Discussion 725-726.
12. Hanke CW, Bernstein G, Bullock S. Safety of tumescent liposuction in 15,336 patients. *Derm Surg* 1995; 21: 459-462.
13. Sommer B, Sattler G, Hanke CW (eds.). *Tumeszenz-Lokalanästhesie. Praktische Anwendung*. Berlin, Heidelberg, Springer, 1999.

14. Lehnhardt M, Homann HH, Drücke D, Steinsträsser L, Steinau HU. Liposuktion - kein Problem? *Chirurg* 2003; 74: 808-814.
15. Lehnhardt M, Homann HH, Druecke D, Palka P, Steinau HU. Liposuktion – kein Problem? Major komplikationen und Todesfälle im deutschsprachigen Raum zwischen 1998 und 2002. *LymphForsch* 2004; 8 (2): 74-78.
16. Berroth R, Speichermann N, Liebau G. Komplikationen nach Liposuction. *Intensivmed* 2003; 40: 237-240.
17. Schmeller W, Meier-Vollrath I. Kommentar zum Artikel: Komplikationen nach Liposuction von Berroth R, Speichermann N, Liebau G. *Intensivmed* 2004; 41: 64-66.
18. Sattler G, Sommer B, Hanke CV (eds.). *Lehrbuch der Liposuktion*. Thieme, Stuttgart 2003.
19. Schmeller W, Meier-Vollrath I. Liposuktion. Leserbrief zum Beitrag Lehnhardt M, Homann HH, Drücke D, Steinsträsser L, Steinau HU (2003) Liposuktion - kein Problem? *Chirurg* 2004; 74: 808-814.
20. Schmeller W, Meier-Vollrath I. Zum aktuellen Stand der Liposuktion. *Dtsch Dermatol* 2002; 9: 590-594.
21. Schmeller W, Meier-Vollrath I. Tumescent liposuction: a new and successful therapy for lipedema. *J Cutan Med Surg* 2006; 10:7-10.
22. Sommer B, Augustin M, Schöpf E, Sattler G. Tumeszenz-Lokalanästhesie. Ein neues Verfahren der Lokalanästhesie. *Dtsch Ärztebl* 2001; 98: A545-548.